

## Human Monkeypox: Clinical Features of 282 Patients

Z. Ježek, M. Szczeniowski, K. M. Paluku,  
and M. Mutombo

*From the Smallpox Eradication Unit, World Health Organization, Geneva, Switzerland; and the Monkeypox Surveillance Team, Kinshasa, Zaire*

We present the clinical features and course of 282 patients with human monkeypox in Zaire during 1980–1985. The ages of the patients ranged from one month to 69 years; 90% were <15 years of age. The clinical picture was similar to that of the ordinary and modified forms of smallpox. Lymphadenopathy, occurring in the early stage of the illness, was the most important sign differentiating human monkeypox from smallpox and chickenpox. The symptoms, signs, and the course of the disease in patients who had been vaccinated against smallpox differed significantly from those in unvaccinated subjects. Pleomorphism and “cropping” similar to that in chickenpox occurred in 31% of vaccinated and 18% of unvaccinated patients. The prognosis depended largely on the presence of severe complications. No deaths occurred among vaccinated patients. In unvaccinated patients the crude case-fatality rate was 11% but was higher among the youngest children (15%).

The first case of human monkeypox was discovered in Basankusu Hospital in the Equateur province of Zaire, where a nine-month-old boy developed a smallpox-like illness in August 1970 [1], one year after the last proved smallpox case had been detected in the area. Monkeypox virus was confirmed to be the causative agent of the boy's illness by the World Health Organization Collaborating Center at the Research Institute for Viral Preparations, Moscow [2]. This discovery was followed by the realization that other cases of suspected smallpox that occurred in Ivory Coast, Liberia, Nigeria, and Sierra Leone in 1970–1971, when smallpox had been eliminated from these countries, were instead cases of human monkeypox [3]. The similarity between the clinical manifestations of monkeypox and smallpox led the Global Commission for the Certification of Smallpox Eradication, in 1980, to recommend that special

surveillance and research should be established in known enzootic areas [4]. Coordinated laboratory and field studies were therefore organized for studying the epidemiology and the natural history of this newly discovered disease, as well as its clinical manifestations. This article reviews the findings of the clinical examination of 282 patients with monkeypox who were interviewed and examined in Zaire from 1980 to 1985.

### Subjects and Methods

In 1980 an intensive health institution-based surveillance program was set up in five specific areas of Zaire covered by dense tropical forest, with a total population of ~5 million (estimated in 1982). A special mobile team, usually composed of an experienced medical officer and two or three nurses/health inspectors, paid several visits to localities where one or more human monkeypox cases had occurred. Persons who showed fever followed by skin eruptions were examined, and clinicoepidemiological diagnoses were subsequently confirmed by laboratory testing of specimens of skin, serum, or both. Relevant personal data, clinical observations, and results of the laboratory tests were entered on standardized investigation sheets. Subsequent follow-up visits to the affected locality were made every seven to 10 days for determining patients' clinical status, completing data and collecting further specimens, and determining whether any additional cases had appeared. A final visit was made four to six weeks

Received for publication 24 November 1986, and in revised form 23 February 1987.

We thank Dr. Kalisa Ruti, former director of the Expanded Immunization Program (Kinshasa, Zaire), for support; R. Barbieri, C. Dunn, B. Otto, M. Wernette, and the staff of surveillance teams participating in the interviews for recording and collecting samples; Dr. S. S. Marennikova (Research Institute for Viral Preparations, Moscow, USSR) and Dr. J. H. Nakano (Centers for Disease Control, Atlanta, Georgia) for laboratory examinations; Dr. F. Fenner (Australian National University, Canberra, Australia) for advice; and Dr. B. Grab for statistical assistance.

Please address requests for reprints to Dr. Z. Ježek, Smallpox Eradication Unit, World Health Organization, 1211 Geneva 27, Switzerland.

after the date of onset of rash in the last case in the locality.

Throughout the investigation great importance was placed on obtaining laboratory confirmation of the clinicoepidemiological diagnoses. Laboratory diagnoses were made by the World Health Organization Collaborating Centers at the Centers for Disease Control (Atlanta) or the Research Institute for Viral Preparations (Moscow). Vesicular and pustular fluids and scabs were examined by electron microscopy and cultured on chicken embryo chorioallantoic membrane and in tissue culture. Sera were tested by HAI test, fluorescent-antibody test, ELISA, RIA, and RIA adsorption test. Sera were also tested for antibody to varicella-zoster virus by fluorescent-antibody (membrane antigen) tests and ELISA so that recent varicella-zoster virus infection could be ruled out.

Statistical significance was assessed by using the  $\chi^2$  test with Yates's correction for continuity.

## Results

**Persons affected.** During the period 1980–1985, 282 individuals with monkeypox were detected, interviewed, and physically examined. The ages of patients ranged from one month to 69 years, but most were children (table 1). Over 90% of the patients were <15 years of age, and more than half were less than five years of age. About 9% were children <12 months of age. There was no significant difference in attack rates between sexes, with 143 (50.7%) cases among males and 139 (49.3%) among females. Thirty-two (11%) of 282 patients had visible smallpox vaccination scars (table 1). Seventeen were adults, and 14 were school-age children, all of whom were vaccinated more than five years before the onset of illness. The youngest vaccinated patient was

a four-year-old boy who was vaccinated shortly after birth who and developed disease four years after primary vaccination. Diagnosis for 209 (74%) of the patients was confirmed by findings of monkeypox virus in lesion material (by electron microscopy, culture on chicken embryo chorioallantoic membrane, and tissue culture) and by serology. Another 61 (22%) patients were detected too late for proper lesion material to be obtained, and their diagnosis was confirmed by serology retrospectively. Twelve (4%) patients died before specimens could be collected, and they were diagnosed on clinical and epidemiological grounds only.

**Clinical features.** The clinical features of human monkeypox are similar to those of the discrete or semiconfluent ordinary or modified type of smallpox. No differences were found in the frequency and extent of various clinical features by sex or age, but they differed according to vaccination status. In general, the clinical course of the illness had two stages: preeruptive and eruptive.

**Preeruptive stage.** Opportunities for observing patients during the preeruptive stage were limited because patients usually sought advice or medical aid only after several days of illness, when lymph nodes enlarged and skin eruptions had already developed. However, the time of onset of fever and of rash could be elucidated by questioning. In most patients the illness started with fever, which lasted in 80% of patients for one to three days before the rash occurred. About 5% of patients developed fever and rash the same day, and the remaining 15% developed rash more than three days after onset of fever. There were no significant differences between unvaccinated and vaccinated patients. The temperature peaked by the second day of the illness and, when taken, was usually between 38.5 and 40.5 C. The febrile illness was accompanied by severe headache, backache, general malaise, and prostration.

**Table 1.** Human monkeypox cases by age, sex, and vaccination status, in Zaire, 1980–1985.

Age group (years)	Males	Females	Total no. examined (%)	Vaccination scar(s)	
				Present	Absent
0–4	66	76	142 (50.3)	1	141
5–9	58	42	100 (35.5)	8	92
10–14	12	8	20 (7.1)	6	14
15–19	1	0	1 (0.4)	1	0
20–29	3	7	10 (3.5)	8	2
30–39	1	4	5 (1.8)	5	0
≥40	2	2	4 (1.4)	3	1
Total (%)	143 (50.7)	139 (49.3)	282 (100.0)	32 (11.3)	250 (88.7)

Next to fever, headache (sometimes frontal but usually generalized) was the commonest symptom and in some patients preceded the onset of fever. In many patients, enlargement of lymph nodes was observed before the onset of rash.

**Eruptive stage.** The skin eruption usually appeared first on the face, but in 18% of patients the rash was first noted on the forearms or some other part of the body. In general, as with smallpox, the lesions developed more or less simultaneously and evolved together in the same body region at the same rate through stages of macules, papules, vesicles, and pustules before umbilicating, drying, and desquamating. The number of skin lesions in individual cases varied from a few to several thousand. A significantly smaller number of lesions was found in vaccinated than in unvaccinated patients ( $\chi^2 = 16.444$ ;  $P < .001$ ). In most patients the degree of fever, severity of symptoms, and duration of illness were proportional to the density of lesions.

Table 2 summarizes the main characteristics of exanthem in patients by different vaccination status. Regional monomorphism (i.e., same form throughout all stages of development) of skin lesions ( $\chi^2 = 5.409$ ;  $P < .05$ ) and centrifugal body distribution of the rash ( $\chi^2 = 20.077$ ;  $P < .001$ ) were significantly better expressed among unvaccinated patients than among vaccinated patients. Pleomorphism and "cropping" occurred in 31% of vaccinated and 18% of unvaccinated patients. The rash was discrete (i.e., the skin lesions were separated by normal skin) in 69% of unvaccinated and 78% of vaccinated patients. A semiconfluent rash (i.e., confluent on the face) was found in 23% of unvaccinated and 22% of vaccinated patients. A confluent rash (i.e., rash confluent on face and forearms) was found in 7% of unvaccinated patients only. Most skin lesions were ~0.5 cm in diameter, but occasionally, lesions up to 1 cm in diameter were seen. The smaller lesions generally occurred in vaccinated subjects. Pocks were more often and more numerous on the faces of unvaccinated persons ( $\chi^2 = 53.047$ ;  $P < .001$ ). Eighty-seven percent of unvaccinated and 47% of vaccinated patients had five or more pocks on their faces. Likewise, pocks on palms and soles were significantly more frequent in unvaccinated than in vaccinated subjects ( $\chi^2 = 27.558$ ;  $P < .001$ ).

Lesions on mucous membranes were observed in 73% of unvaccinated and 37% of vaccinated patients. Exanthem in the oral cavity, which sometimes evolved rapidly to produce painful lesions, was twice

**Table 2.** Main characteristics of exanthem in patients with monkeypox by vaccination status.

Main characteristics of exanthem	No. of patients (%) with vaccination scar	
	Absent	Present
Regional occurrence		
Monomorphisms	203 (81.8)	20 (62.5)
Pleomorphisms	45 (18.2)	10 (31.2)
Indefinite	0 (0.0)	2 (6.3)
Total observed	248 (100.0)	32 (100.0)
Body distribution		
Centrifugal	201 (81.1)	14 (43.7)
Centripetal	13 (5.2)	3 (9.4)
Indefinite	34 (13.7)	15 (46.9)
Total observed	248 (100.0)	32 (100.0)
Characteristics		
Discrete	172 (69.3)	25 (78.1)
Semiconfluent	58 (23.4)	7 (21.9)
Confluent	18 (7.3)	0 (0.0)
Hemorrhagic	0 (0.0)	0 (0.0)
Total observed	248 (100.0)	32 (100.0)
Presence of pocks		
Facial	217 (97.3)	19 (59.4)
Palmar	182 (81.6)	12 (37.5)
Plantar	154 (69.9)	10 (31.2)
Total observed	223	32

as frequent in unvaccinated than in vaccinated patients. Many patients complained of sore throats. Conjunctivitis and edema of the eyelids were common and caused considerable but temporary distress to the affected patients. Seventeen percent of unvaccinated and 13% of vaccinated patients had focal lesions on the conjunctiva and along the margins of eyelids. Twenty-seven percent of unvaccinated and 10% of vaccinated patients had multiple and painful lesions on genitalia. Symptoms of an attack of acute tonsillitis with or without signs of pharyngitis were observed in 52% of unvaccinated and 41% of vaccinated patients. Symptoms of pharyngeal and laryngeal involvements were noted in many unvaccinated patients. Coughing with or without sputum production was a relatively common symptom, being observed in 39% of unvaccinated and 14% of vaccinated patients.

With the onset of the rash the fever fell in 46% of the patients whose body temperature was measured during hospitalization. More than half of the others had a temperature of  $\geq 39$  C at the time of onset of rash. Moderate fever occurred in 43% of patients on the second day and 27% the third day after appearance of the rash. A second febrile period, lasting for two or three days and associated with de-

terioration in the patients' general condition, occurred in 37% of patients when the skin eruptions became pustular during the second week of the illness.

Temporary enlargement of lymph nodes was more frequently present in unvaccinated patients (84%) than in vaccinated ones (53%;  $\chi^2 = 15.082$ ;  $P < .001$ ). Lymphadenopathy occurred at an early stage of illness in most cases, occasionally at the time of onset of fever, usually on the second and third day of the illness. Occasionally it was first seen one or two days after the onset of the rash. Some patients sought medical help because of lymphadenitis and fever and developed a skin rash after admission to the health establishment. Enlarged lymph nodes of 1–4 cm (usually the size of a pigeon's egg) were firm, tender, and occasionally painful. In most cases there was edema of surrounding subcutaneous tissue, but the overlying skin was unchanged. Initially, enlargement of the nodes was more common in the neck area (submaxillar and cervical lymph nodes), but two or three other node-bearing areas were usually affected later in the course of illness. Generalized lymphadenopathy was observed in 59% of unvaccinated and 47% of vaccinated patients who showed signs of enlarged lymph nodes. Abscess formation in the axilla or groin was observed in a few cases.

**Course of illness.** The course of illness lasted two to four weeks, depending on the severity of the illness. In most cases scabs fell off by day 22–24 after onset of illness. Figure 1 shows the interval between onset of illness and convalescence in observed patients, according to vaccination status. Desquamation of crusts left areas of hypopigmentation, followed after a few weeks by hyperpigmentation, which gradually diminished with time.

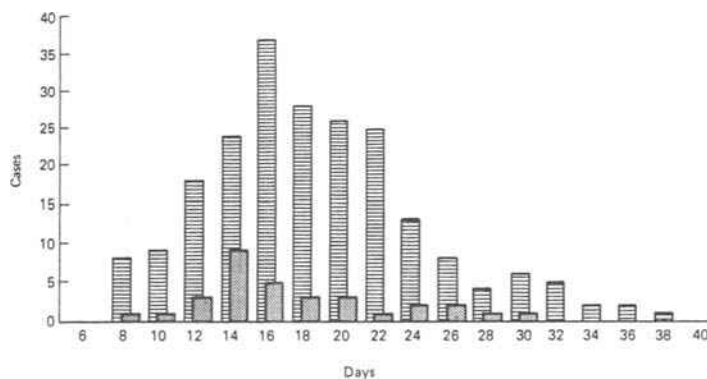
**Table 3.** Incidence of main complications by vaccination status of affected patients.

Complications	No. of patients (%) with vaccination scar	
	Absent	Present
None	143 (57.2)	29 (90.7)
Secondary bacterial infection of skin (boils, abscesses, septic dermatitis)	48 (19.2)	1 (3.1)
Bronchopneumonia, pulmonary distress	29 (11.6)*	1 (3.1)
Vomiting, diarrhea, dehydration marasmus	17 (6.8)	0 (0.0)
Keratitis, corneal ulceration	11 (4.4)	1 (3.1)
Septicemia	1 (0.4)†	0 (0.0)
Encephalitis	1 (0.4)†	0 (0.0)
Total observed	250 (100.0)	32 (100.0)

\* Nineteen fatal.

† One fatal.

**Complications, sequelae, and prognosis.** The commonest but least serious complications involved the skin (which was swollen and stiff and sometimes painful) in almost every case until the rash reached the scabbing stage. Secondary infection of skin lesions resulting in boils, cutaneous or subcutaneous abscesses, and septic dermatitis caused great discomfort in 19% of unvaccinated patients. Table 3 shows the incidence of more serious complications, which occurred in nearly 43% of unvaccinated and 9% of vaccinated patients. Pulmonary distress and bronchopneumonia, occurring in the later stage of illness, affected 29 (12%) of unvaccinated patients, 19 of whom died. Vomiting and diarrhea in the second week of illness, leading to severe dehydration and deterioration of general health, occurred in 7% of



**Figure 1.** Interval between onset of illness and convalescence in patients with monkeypox by vaccination status, i.e., vaccination scar absent (hatched columns) or present (dotted columns).

**Table 4.** Age- and sex-specific case-fatality rates among 250 unvaccinated patients with monkeypox.

Age-group (years)	No. dying/no. of cases (%)		
	Males	Females	Total
0-4	9/66 (13.6)	12/75 (16.0)	21/141 (14.9)
5-9	4/53 (7.5)	2/39 (5.1)	6/92 (6.5)
≥10	0/10 (0.0)	0/7 (0.0)	0/17 (0.0)
Total	13/129 (10.1)	14/121 (11.6)	27/250 (10.8)

unvaccinated patients. Corneal ulceration was seen in 4% of unvaccinated patients at the end of the second week of illness. One patient, a five-year-old unvaccinated boy who had >4,500 skin lesions, died of septicemia, and a three-year-old unvaccinated girl developed encephalitis and died in a coma the second day after admission to the hospital.

The commonest sequelae were the pitted scars that developed on the face of most unvaccinated and about half of vaccinated persons. However, in patients without secondary bacterial infections, the scars were superficial and were likely to disappear, but about half of the scars from lesions seen initially on the face and body were detectable two to four years after illness. Serious sequelae were observed in 8% of unvaccinated and 6% of vaccinated patients. A four-year-old unvaccinated girl was blinded in both eyes, and three other unvaccinated children, one 11 months old and two five years old (a boy and a girl), were affected with unilateral blindness. Corneal opacities of various degrees resulting in impaired vision occurred in six other unvaccinated children and one vaccinated child. Scars deforming eyelids, lips, or nares were seen in 2% of unvaccinated patients. Two percent of other patients developed cicatricial keloids on the neck, in the axilla, and in the groin. One three-year-old girl developed partial alopecia.

In contrast to variola major, the prognosis of patients with human monkeypox depends largely on the presence or absence of severe complications, which depend on several factors, including previous vaccination status, initial health status, and concurrent illnesses such as measles, malaria, or diarrheal disease.

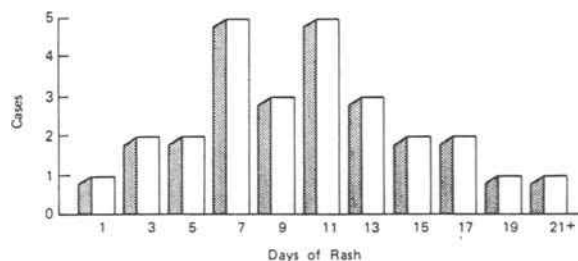
No deaths occurred among patients with a visible vaccination scar, but there were 27 deaths among 250 patients without vaccination scars (crude case-fatality rate, 11%). All deaths occurred in children between three months and eight years of age. The

age-specific case-fatality rate in the youngest age-group was more than twice that for older children (table 4). Twenty-three percent of those who died did so within the first week, 55% during the second week, and the remaining 22% during the third week after onset of illness (figure 2). Deaths were sporadic, and no clustering in place or time was observed.

## Discussion

Humans are the sole natural host of two poxviruses: variola and molluscum contagiosum viruses. In addition, humans are susceptible to infection with other orthopoxviruses with a wide host range, such as vaccinia and cowpox viruses. During the smallpox eradication program, a new generalized orthopoxvirus disease in humans was discovered that was caused by monkeypox virus. This disease, called "human monkeypox," is a rare and sporadic zoonosis occurring in remote areas of the tropical rain forests in central and western Africa [5]; hence investigation of its natural history and examination of patients with this disease have been difficult.

Earlier descriptions of the clinical features of human monkeypox, based on 47 cases detected in the 1970s [6] and 57 cases diagnosed up to the end of 1981 [7], need revision in the light of the additional experience gained through a special effort in Zaire during the years 1980-1985. Clinically, human monkeypox is similar to the ordinary or modified type of smallpox; no patient has been seen with clinical symptoms and signs comparable to flat-type or hemorrhagic-type smallpox [8]. Over 90% of the patients were children <15 years of age, and death was noted only among those <10 years of age. In human monkeypox, as in smallpox [9], vaccination with vaccinia virus and the resulting immune status of an exposed individual are the major determinants of susceptibility to infection. Immunity in formerly

**Figure 2.** Interval between onset of rash and death (in days) of 27 patients with monkeypox who died.

vaccinated persons now appears to be waning; 32 (11%) of 282 patients who developed the illness during 1980–1985 had visible vaccination scars. However, the residual immunity substantially reduced the severity and frequency of signs and symptoms and the frequency of complications and sequelae; no deaths occurred among patients with visible vaccination scars.

Pleomorphism and “cropping” of the rash occurred in 31% of vaccinated and 18% of unvaccinated patients (table 2), among whom the indefinite distribution or concentration of the rash on the trunk rather than the limbs and the absence of pocks on the face, palms, and soles were suggestive of chickenpox. Thus, differentiation from chickenpox is the main diagnostic problem, especially in patients with vaccination scars. Five persons who had been vaccinated several years previously developed only one or two lesions on the body, an observation further emphasizing that some cases can be exceedingly mild and would go unreported in the absence of adequate surveillance.

The only clinical sign differentiating human monkeypox from smallpox and chickenpox is the pronounced lymph node enlargement, which occurred in 84% of unvaccinated and 53% of vaccinated patients.

Complications of two kinds were seen: the first due to viral activity and the other to secondary bacterial infections. The latter were especially important because most patients lived in small remote localities close to the tropical forest, where hygienic conditions were poor and antibiotics not readily available. Skin complications were common and added to the patient’s discomfort, but they were usually not serious. Symptoms of respiratory and pulmonary distress late in the course of illness suggested secondary infection of the lungs.

In the setting in which examinations were done, registering every complication or determining every sequela was difficult; some of the affected children left hospitals or their homes before complete recovery from the illness. Nevertheless, the recorded complications (table 3) and mentioned sequelae are relatively common and may be serious. Combined with the high case-fatality rate, especially in young children, these features make human monkeypox the most important orthopoxvirus infection presently occurring in humans.

#### References

1. Ladnyj ID, Ziegler P, Kima E. A human infection caused by monkeypox virus in Basankusu Territory, Democratic Republic of the Congo. *Bull WHO* 1972;**46**:593–7
2. Marennikova SS, Šeluhina EM, Mal'ceva NN, Čimiškjan KL, Macevič GR. Isolation and properties of the causal agent of a new variola-like disease (monkeypox) in man. *Bull WHO* 1972;**46**:599–611
3. Foster SO, Brink EW, Hutchins DL, Pifer JM, Lourie B, Moser CR, Cummings EC, Kuteyi OEK, Eke REA, Titus JB, Smith EA, Hicks JW, Foegel WH. Human monkeypox. *Bull WHO* 1972;**46**:569–76
4. World Health Organization. The global eradication of smallpox. Final report of the Global Commission for the Certification of Smallpox Eradication. Geneva: World Health Organization, 1980
5. Arita I, Ježek Z, Khodakevich L, Ruti K. Human monkeypox: a newly emerged orthopoxvirus zoonosis in the tropical rain forests of Africa. *Am J Trop Med Hyg* 1985;**34**:781–9
6. Breman JG, Ruti K, Steniowski MV, Zanotto E, Gromyko AI, Arita I. Human monkeypox, 1970–79. *Bull WHO* 1980;**58**:165–82
7. Ježek Z, Gromyko AI, Szczeniowski MV. Human monkeypox. *J Hyg Epidemiol Microbiol Immunol* 1983;**27**:13–28
8. Rao AR. Smallpox. Bombay: Kothari Book Depot, 1972
9. Mack TM, Thomas DB, Ali A, Khan MM. Epidemiology of smallpox in West Pakistan. I. Acquired immunity and the distribution of disease. *Am J Epidemiol* 1972;**95**:157–68